

## Research Article

**Evaluation of Hepatoprotective Activity of Ethanolic Extract of Whole Plant of Hibiscus Platanifolius Linn in Rifampicin Induced Hepatotoxicity in Wistar Albino Rats**

M.Madhu Babu\*, A.Lakshmana rao

Department of Pharmacology, V. V. Institute of Pharmaceutical Sciences, Gudlavalleru, Andhra Pradesh, INDIA

Received February 06, 2018; Accepted March 03, 2018; Published March 05, 2018

Copyright: © 2018 Babu MM, et al

\*Corresponding author: M.Madhu Babu, Department of Pharmacology, V. V. Institute of Pharmaceutical Sciences, Gudlavalleru, Andhra Pradesh, INDIA. E-mail: [morthamadhu@gmail.com](mailto:morthamadhu@gmail.com)

**Abstract**

The aim of present study was to investigate hepatoprotective activity of ethanolic extract of whole plant of *Hibiscus platanifolius* Linn in rifampicin induced hepatotoxicity in wistar albino rats in which hepatotoxicity was induced by rifampicin (1000 mg/kg, b.wt) for every 72 hours up to 15 days and followed by treatment with standard agent silymarin (25mg/kg, b.wt), and ethanolic extract of test in two different doses. On 16th day blood was collected from the rat by retro orbital puncture and biochemical parameters like ALT, AST, ALP, Direct Bilirubin, Total Bilirubin, Triglycerides, Cholesterol, Total Proteins and Albumin were estimated. The animals were sacrificed by overdose of ether autopsied. Livers from all animals were removed, washed with ice-cold saline, weighed and measured the wet liver volume. Small piece of liver tissue was collected and preserved in 10% formalin solution for histopathological studies. Biochemical parameters and histopathological studies were concluded that plant extract had hepatoprotective activity

**Keywords:** *Hibiscus Platanifolius* Linn; Rifampicin; Silymarin; SGOT; SGPT; ALP; Bilirubin.

**Introduction**

Hepatotoxicity refers to any disorder of the liver which includes the following conditions: steatosis or fatty deposits in the liver, fibrosis or scarring of the liver, hepatitis or inflammation of the liver, cirrhosis where scarring and inflammation spread through the liver and irreversibly disrupt its shape or function causing permanent cell damage and ultimately liver failure and leading to liver cancer which causes ultimately liver failure and death [1].

Hepatotoxicity is caused by various toxicants such as paracetamol, certain chemotherapeutic agents, carbon tetrachloride, thioacetamide, chronic alcohol consumption and microbes [2]. Most of the population in world is suffering from liver disease. About 20,000 deaths found every year due to liver disorders [3]. Female to male ratio of hepatotoxicity was found to be 1.4:1 at age 39. The prevalence of various types of hepatotoxicity for jaundice, acute hepatitis, cholestasis, cholestatic hepatitis, acute and chronic liver injury

was found to be 60.4%, 41.4%, 15.5%, 24.1%, 4.5% and 8.6% respectively [4].

Several different substances can be toxic to the liver such as viruses (hepatitis a, hepatitis b, hepatitis c, hepatitis d), obesity, chronic or long-term alcohol use, genetic defects (haemochromatosis), drugs like pcm, aspirin, ibuprofen, amiodarone, isoniazid, methotrexate, valproic acid, rifampin, etc., poisons like ccl<sub>4</sub>, trichloroethylene, etc., autoimmune disorder, herbs like cascara, mahuang, kava etc., hormones like birth control pills, anabolic steroids [5], [6].

There are no specific allopathic medicines use as hepatoprotective but there are some drugs used to treat the symptoms of hepatotoxicity such as cholestyramine, ursodeoxycholic acid, cetirizine, naltrexone, spironolactone, furosemide, propranolol, loratidine, vasopressin having certain disadvantage such as diarrhea, constipation, flatulence, abdominal discomfort, variable response, and may aggravates encephalopathy [7], [8].

Herbal-based therapeutics for liver disorders has been in use in India for a long time and has been popularized world over by leading pharmaceuticals. The use of natural remedies for the treatment of liver diseases has a long history, starting with the ayurvedic treatment, and extending to the Chinese, European and other systems of traditional medicines. The 21<sup>st</sup> century has seen a paradigm shift towards therapeutic evaluation of herbal products in liver disease models by carefully synergizing the strengths of the traditional systems of medicine with that of the modern concept of evidence based medicinal evaluation, standardization and randomized placebo controlled clinical trials to support clinical efficacy [9].

Liver protective herbal drugs contains a variety of chemical constituents like phenol, coumarins, lignans, essential oil, monoterpenes, carotenoids, glycosides, flavonoids, lipids, alkaloids and xanthenes, which are responsible for the hepatoprotective activity [10].

In the traditional system of Indian medicine plant formulation and combined extract of plants are used as a drug of choice rather than individual drug. Various herbal formulations are well known for their hepatoprotective effect [11]. In recent years, there is growing interest in polyherbal formulation for the treatment of various diseases and it has enormously increased worldwide. Polyherbal formulations have shown curative effect on liver diseases and disorders in rats [12].

While searching for hepatoprotective drug in natural product, highly encouraging result was obtained in our laboratory with polyherbal formulation of *Momardica charantia* and *Azadirachta indica* A. Juss (neem) [13]. The present investigation is undertaken to study hepatoprotective effect of ethanolic extract (*Hibiscus platanifolius* Linn) on rifampicin induced hepatotoxicity in rats.

Liver is the largest gland of the body enclosed within the right lower rib cage beneath the diaphragm. It is almost completely covered by visceral peritoneum and a dense irregular connective tissue layer that lies deep to the peritoneum. Liver is divided in two principle lobes, a large right lobe and a smaller left lobe separated by falciform ligament. The right lobe is considered by many anatomists to include an inferior quadrate lobe and a posterior quadrate lobe. The liver receives blood from two sources, from hepatic artery it obtains oxygenated blood and from hepatic portal vein it receives deoxygenated blood containing newly absorbed nutrients. Branches of both the hepatic artery and the hepatic portal vein carry blood into liver sinusoids, where oxygen, most of the nutrients and certain poisons are excreted by hepatic cells. The reticuloendothelial (Kuffer's) cells lining the sinusoids phagocytes microbes and foreign matter from the blood. Branches of hepatic portal vein, hepatic artery and bile duct typically accompany each other in their distribution through the liver. Collectively, these structures are called as Portal triad. Liver has functions like production of fibrinogen, prothrombin, heparin, and other clotting factors VII, VIII, destruction of erythrocytes.(at the end of their respective life

span), circulatory function, transfer of blood from portal to systemic circulation, Blood storage (regulation of blood volume), detoxification and protective functions, kupffer cells remove foreign bodies from blood (phagocytosis), detoxification by conjugation, methylation, oxidation and reduction.

Several different substances can be toxic to the liver such as viruses (hepatitis a, hepatitis b, hepatitis c, hepatitis d), obesity, chronic or long-term alcohol use, genetic defects (haemochromatosis), drugs like PCM aspirin, ibuprofen, amiodarone, isoniazid, methotrexate, valproic acid, rifampin, etc., poisons like CCL<sub>4</sub>, trichloroethylene, etc., autoimmune disorder, herbs like cascara, mahuang, kava etc., hormones like birth control pills, anabolic steroids. There are no specific allopathic medicines use as hepatoprotective but there are some drugs used to treat the symptoms of hepatotoxicity such as colestyramine, ursodeoxycholic acid, cetirizine, naltrexone, spironolactone, furosemide, propranolol, loratidine, vasopressin having certain disadvantage such as diarrhea, constipation, flatulence, abdominal discomfort, variable response, and may aggravates encephalopathy.

## **Materials and Methods**

### **Plant material**

The plant *Hibiscus platanifolius* was collected during the march 2014 from Sri Venkateshwara University Tirupati, India. The plant was authenticated by Dr.Madhava Chetty, Department of Botany and voucher specimen of the plant were preserved at institute herbarium library.

### **Preparation of plant extracts**

Fresh plants collected, were washed to remove adhered dirt, rinsed with distilled water, blotted and dried in shade. The shade-dried specimens were powdered in a mixer. This powder was used for solvent extraction. About 100 g of the powdered plant material was subjected to Soxhlet extraction using 100 ml solvent ethanol. This cycle was repeated many times, over

hours or a few days, until the colour of the solvent in the siphon of the soxhlet faded away. The extracts were concentrated under reduced pressure and preserved in refrigerator until further use. At the end of the hot extraction process each extract was filtered. The filtrate was concentrated and the solvent was recovered using rotary evaporator. The extracts were then kept in desiccators to remove remaining moisture, if present, and finally stored in air tight containers at 4°C for further use.

### **Experimental animals**

Male albino rats (Wistar strain) weighing between 150-200 g are procured from Nutritional Society of India, Taranaka, Hyderabad. The animals were acclimatized for seven days under laboratory conditions. The animals were fed with commercially available rat pelleted diet. Water was allowed ad libitum under strict hygienic conditions. The study protocols were duly approved by the Institutional Animal Ethics Committee (IAEC). Studies were performed in accordance with CPCSEA guidelines.

### **Phytochemical Screening**

Phytochemical Screening Standard methods were used for preliminary phytochemical screening of ethanolic extracts, to know the nature of phytoconstituents present in it.

### **Acute toxicity testing**

Acute toxicity study was determined as per OECD Guideline 425.

Studies were carried out in order to check the toxic effects of the extracts. The study was performed as per Organization for Economic Cooperation and Development (OECD) guidelines no 425. Rats were used for this purpose. The animals were fasted overnight, providing on water, after which the extract was administered to the respective groups orally at the dose level of 2000 mg/kg body weight by gastric intubation and the groups were observed continuously for 24 hrs for behavioral,

neurological and autonomic profiles, and then at 24 hrs and 72 hrs for an lethality. The animals were further observed for toxic symptoms for 14 days. According to the guidelines if mortality is observed in 2 or 3 animals, then the dose administered is assigned as toxic dose. If mortality is observed in one animal, then the same dose is repeated again to confirm the toxic dose. If mortality is not observed at all, the plant extract is considered as alternatively, the toxicity test is started with a dose of 100 mg/kg body weight and repeated for further other doses such as 250, 500, 1000 and finally 2000 mg/kg body weight.

### **Effect of extract as Hepatoprotective**

Healthy Wistar strain albino rats were selected and randomly divided into five groups with six animals in each group serving as

1. Group 'A' = normal,
2. Group 'B' = hepatotoxic control,
3. Group 'C' = reference control i.e. standard drug (Silymarin, 25 mg/kg b. wt.).
4. Group 'D' = hepatotoxic group given 200 mg/kg b. wt of the extract,
5. Group 'E' = hepatotoxic group given 400 mg/kg b. wt of the extract, (here taken 1/10<sup>th</sup> & 1/5<sup>th</sup> test doses from acute toxicity test dose i.e. 2000 mg/kg).

An identification mark was given to the rats of each group using picric acid as dye following standard procedure of (Animal identification marking)]. Each rat of a group was marked at a specific position viz.- Head; Back; Tail; Head and Back; Head and Tail; and one was left Blank i.e. unmarked. Each rat was weighed and the doses were calculated accordingly.

Hepatotoxicity was induced in each group using freshly prepared solution of Rifampicin dissolved in normal saline (0.91% w/v of NaCl) except the group "A" which served as normal control. For inducing hepatotoxicity the rats were kept on fasting for 18 hours and hepatotoxicity was induced by giving oral route of Rifampicin (1000 mg/kg b. wt.)

Rifampicin was given for every 72 hours but standard and extract was given daily upto 15 days. on 16<sup>th</sup> day blood was collected from the rat by retro orbital puncture and biochemical parameters like ALT, AST, ALP, Direct Bilirubin, Total Bilirubin, Triglycerides, Cholesterol, Total Proteins and Albumin were estimated. The animals were sacrificed by overdose of ether autopsied. Livers from all animals were removed, washed with ice-cold saline, weighed and measured the wet liver volume. Small piece of liver tissue was collected and preserved in 10% formalin solution for histopathological studies.

### **Statistical analysis**

Data were analyzed by one-way ANOVA followed by Dennett's t-test using Instant<sup>®</sup> (Graph Pad software, U.S.A). At 95% confidence interval  $p < 0.05$  was considered statistically significant.

### **Results and Discussion**

The strong presence of desired phytochemicals in ethanolic extracts when compared to methanolic and chloroform extracts. Hence, for the further studies ethanolic extract of *Hibiscus Platanifolius* have been selected.

### **Toxicity study**

In the present study the ethanolic extract of *Hibiscus platanifolius* leaves were subjected for toxicity studies.

hyto constituents	Test	Methanolic Extract	Chloroform Extract	Ethanollic Extract
Carbohydrates	Mohlish's test	-	-	+
	Fehling's test	-	+	+
Proteins and amino acids	Ninhydrin test	-	-	-
	Biuret test	-	-	-
Alkaloids	Mayer's test	-	-	-
	Wagner's test	-	-	-
Fixed oils and fats	Spot test	-	-	-
Glycosides	Borntrage's test	-	-	-
	Legal's test	-	-	-
Triterpenoids	Tin + thionyl chloride	-	-	+
Phenolics and tannins	Ferric chloride test	-	-	-
	Gelatin test	-	-	-
	Lead acetate test	-	-	-
	Alkaline reagent test	-	-	-
	Dilute HNO <sub>3</sub> test	-	-	-
Saponins	Foam test	-	-	-
	Haemolysis test	-	-	-
Flavones and Flavonoids	Caddy's test	-	+	+
	Shinoda test	+	-	+

“+” Present and “-” Absent

**Table 1:** Phytochemical constituents present in ethanolic extract of whole plant of Hibiscus platanifolis

For the LD<sub>50</sub> dose determination, ethanolic extract was administered up to dose 4 gm/kg body weight and extract did

not produce any mortality, thus 1/5<sup>th</sup> (400 mg), 1/10<sup>th</sup> (200 mg) of maximum dose tested were selected for the present Study.

LD<sub>50</sub> of extracts of *Hibiscus platanifolius* were calculated and found to be 2000 mg/kg

### Hepatoprotective activity

#### Biochemical parameters

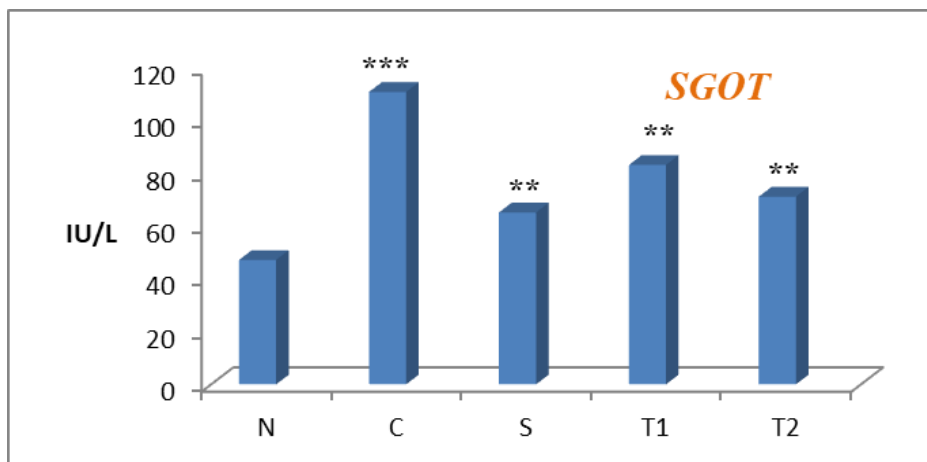
**Effect of ethanolic whole plant extract of *Hibiscus platanifolius* on biochemical parameters in rifampicin induced hepatotoxic rats.**

Rats treated with rifampicin developed a significant hepatic damage observed as elevated serum levels of hepatospecific enzymes like SGPT, SGOT and ALP when compared to normal control. Pretreatment with Silymarin, ethanolic extract had showed good protection against rifampicin induced toxicity to liver. Test indicates a significant reduction in elevated serum enzyme levels with extract treated animals (Figure 1-3).

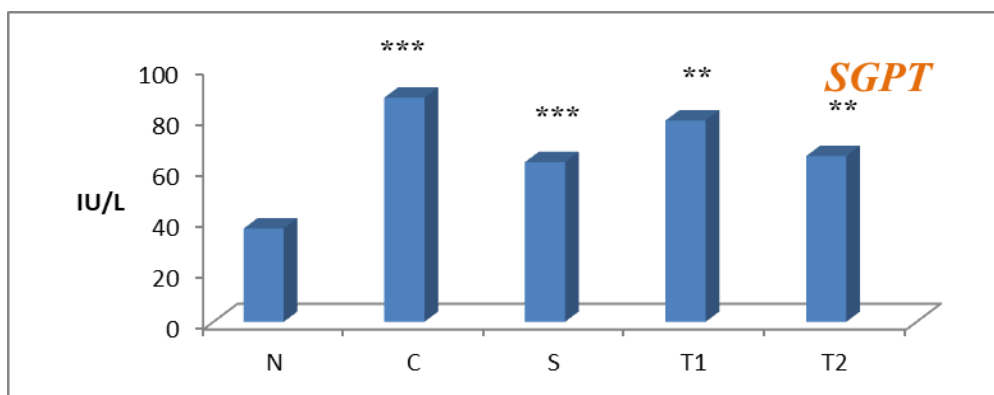
Group	Treatment	Dose	SGPT levels (IU/L)	SGOT levels (IU/L)	ALP levels (IU/L)
A	Normal control	10ml/kg, p.o.	36.7±2.007	47.16±2.006	120.83±2.001
B	Rifampicin control	1 gm/kg, p.o.	88.16±2.017***	110.83±2.007***	240.83±2.007***
C	Standard	25mg/kg, p.o.	62.8±2.007**	65.16.16±2.007**	80.83±2.007***
D	EEHP	200mg/kg, p.o.	79.16±2.007**	83.16±2.007**	129.16±2.007**
E	EEHP	400mg/kg, p.o.	65.16 ±2.007**	71.16±2.016**	95.83±1.536**

**Table 2:** Effect of ethanolic extract of whole plant of *Hibiscus platanifolius* on SGPT, SGOT & SALP levels in rifampicin induced hepatotoxic rats.

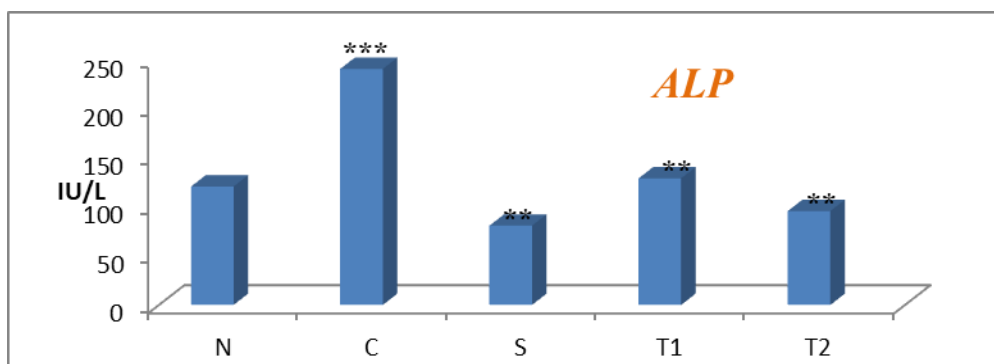
Values are mean ± SEM (n=6) one way ANOVA by using Graph Pad Prism 5. Where, \* represents significant at p<0.05, \*\* represents highly significant at p< 0.01, and \*\*\* represents very significant at p<0.001. All values are compared with toxicant.



**Figure 1:** Effect of ethanolic extract of whole plant of *Hibiscus platanifolius* on SGOT levels in rifampicin induced hepatotoxic rats.



**Figure 2:** Effect of ethanolic extract of whole plant of *Hibiscus platanifolius* on SGPT levels in rifampicin induced hepatotoxic rats.



**Figure 3:** Effect of ethanolic extract of whole plant of *Hibiscus platanifolius* on ALP levels in rifampicin induced hepatotoxic rats

### Direct bilirubin and total bilirubin

Elevation of direct and total bilirubin levels after administration of rifampicin indicate hepatotoxicity. Pretreatment with silymarin, ethanolic extract significantly

reduced levels of direct and total bilirubin levels when compared to toxic control group indicating Hepatoprotective effect of ethanolic extract of whole plant of *Hibiscus platanifolius* (Figure 4-12).

Group	Treatment	Dose	Direct bilirubin levels (mg/dl)	Total bilirubin levels (mg/dl)
A	Normal control	10ml/kg, p.o.	0.711±0.020	1.25±0.228
B	Rifampicin control	1gm/kg, p.o.	1.09±0.020***	2.15±0.097***
C	Standard	25mg/kg, p.o.	0.41±0.020**	0.83±0.097*
D	EEHP	200mg/kg, p.o.	0.31±0.025**	0.75±0.063*
E	EEHP	400mg/kg, p.o.	0.39±0.024**	0.74±0.097*

**Table 3:** Effect of ethanolic extract of whole plant of *Hibiscus platanifolius* on direct bilirubin & Total Bilirubin, Cholesterol levels in rifampicin induced hepatotoxic rats.

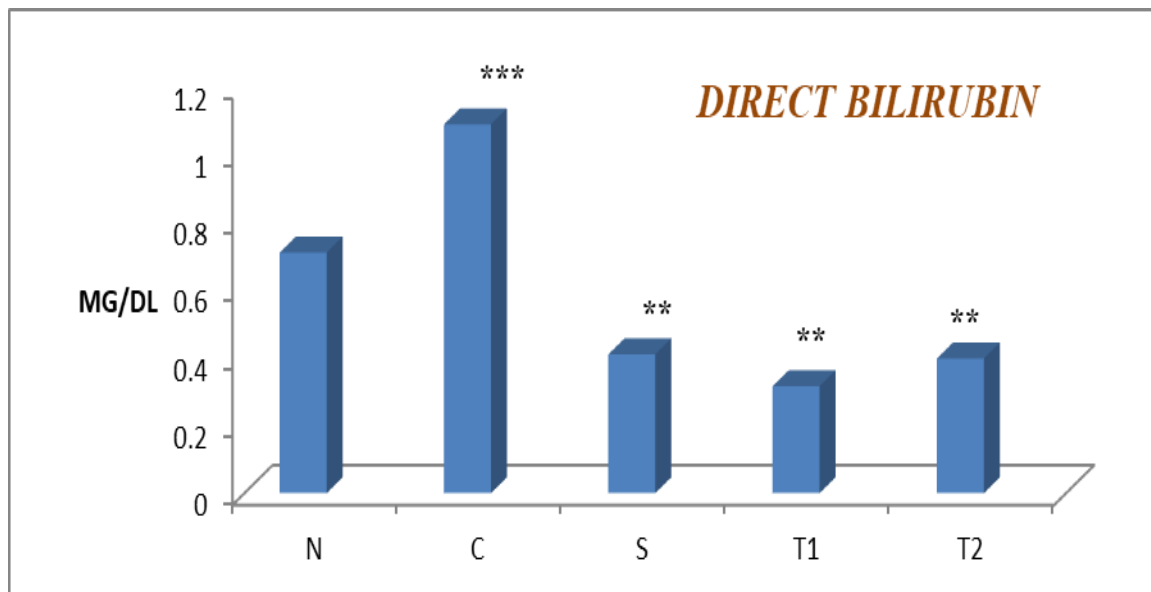
Values are mean  $\pm$  SEM (n=6) one way ANOVA.

Where, \* represents significant at  $p < 0.05$ , \*\* represents highly significant at  $p < 0.01$ , and \*\*\* represents very significant at  $p < 0.001$ . All values are compared with toxicant.

Group	Treatment	Dose	Cholesterol (mg/dl)	Total protein (mg/dl) ( U/L )
A	Normal control	10ml/kg, p.o.	29.6 $\pm$ 0.897	8.74 $\pm$ 1.204
B	Rifampicin control	1 gm/kg, p.o.	76.06 $\pm$ 0.897***	14.73 $\pm$ 1.180***
C	Standard	25mg/kg, p.o.	42.32 $\pm$ 0.805***	12.72 $\pm$ 1.080**
D	EEHP	200mg/kg, p.o.	49.38 $\pm$ 0.897**	13.13 $\pm$ 0.996**
E	EEHP	400mg/kg, p.o.	46.18 $\pm$ 0.897**	12.98 $\pm$ 0.94**

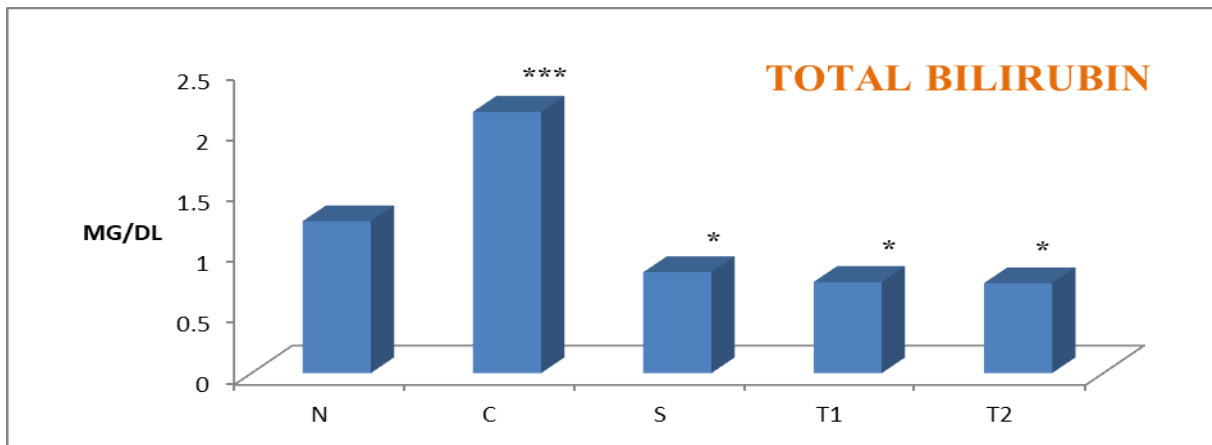
**Table 4:** Effect of ethanolic extract of whole plant of *Hibiscus platanifolius* on, Cholesterol & total proteins levels in rifampicin induced hepatotoxic rats.

Values are mean  $\pm$  SEM (n=6) one way ANOVA .Where, \* represents significant at  $p < 0.05$ , \*\* represents highly significant at  $p < 0.01$ , and \*\*\* represents very significant at  $p < 0.001$ . All values are compared with toxicant.

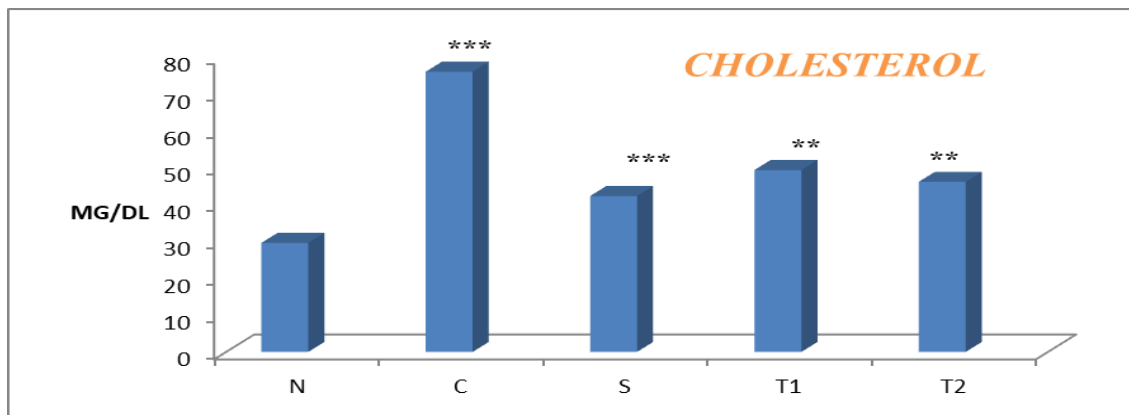


**Figure 4:** Effect of ethanolic extract of whole plant of *Hibiscus platanifolius* on Direct Bilirubin levels in rifampicin induced hepatotoxic rats.

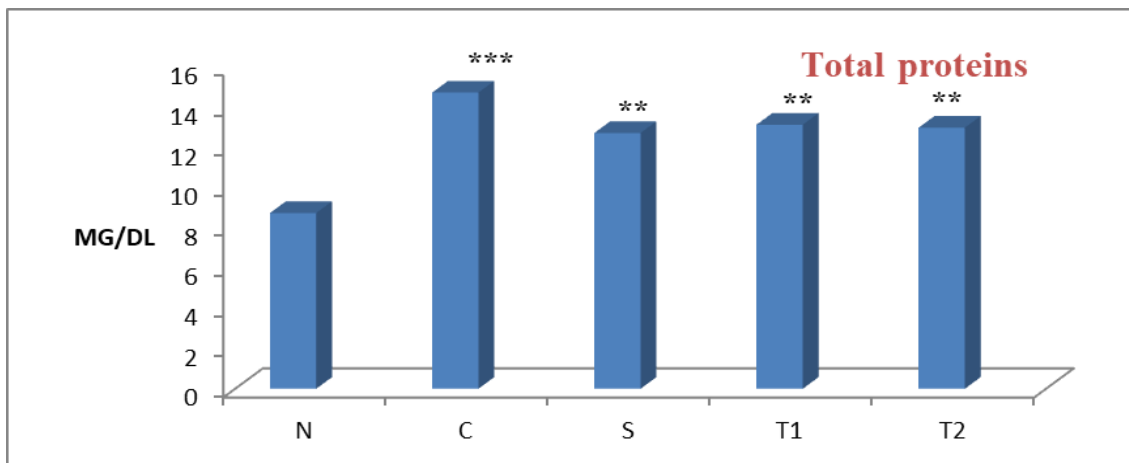




**Figure 5:** Effect of ethanolic extract of whole plant of *Hibiscus platanifolius* on total Bilirubin levels in rifampicin induced hepatotoxic rats.



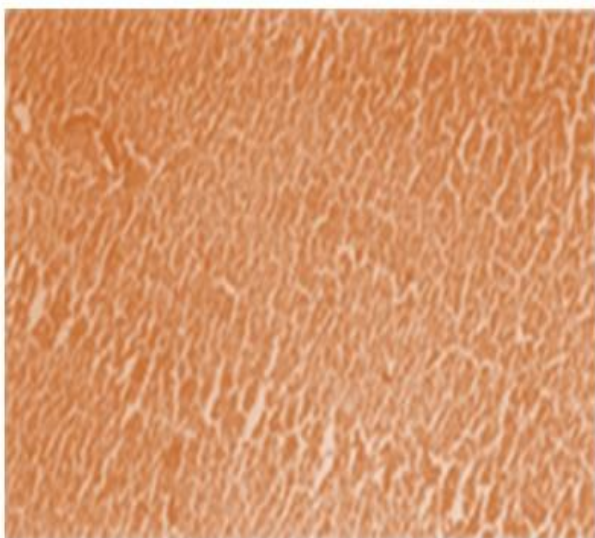
**Figure 6:** Effect of ethanolic extract of whole plant of *Hibiscus platanifolius* on cholesterol levels in rifampicin induced hepatotoxic rats.



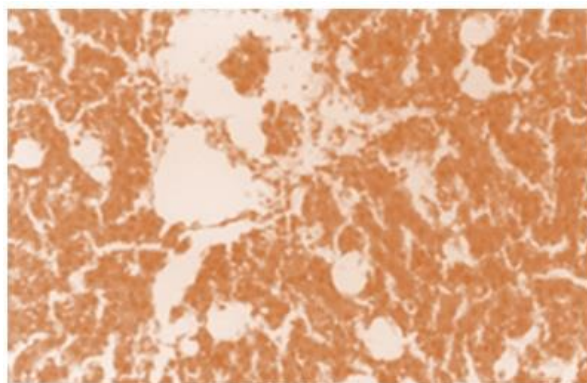
**Figure 7:** Effect of ethanolic extract of whole plant of *Hibiscus platanifolius* on total proteins levels in rifampicin induced hepatotoxic rats.

## Histopathological studies of the liver in rifampicin induced hepatotoxicity

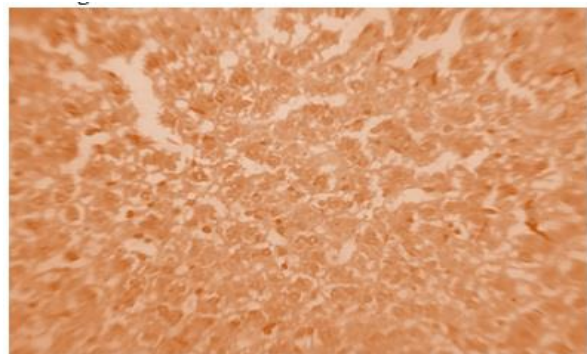
- The histopathological evaluation of rifampicin toxicity in all the groups was examined and shown
- Photomicrograph of liver tissue of control (normal) rats showing portal triad with normal hepatocytes
- Photomicrograph of rat liver tissue of rifampicin treated groups showing necrotic cells around the central vein, fatty changes and inflammatory cells.
- Photomicrograph of rat liver tissue of rifampicin and Standard treated rats showing Cords of hepatocytes with central vein and portal triads -Mild lymphocytic infiltrate in portal triad vein.
- Photomicrograph of rat liver tissue of rifampicin and T1 treated rats showing macrophage infiltration and improvement of histological appearance with less evidence of necrosis.
- Photomicrograph of rat liver tissue of rifampicin and T2 treated rats showing regenerated tubular epithelium and healing by fibrosis of the necrotic.



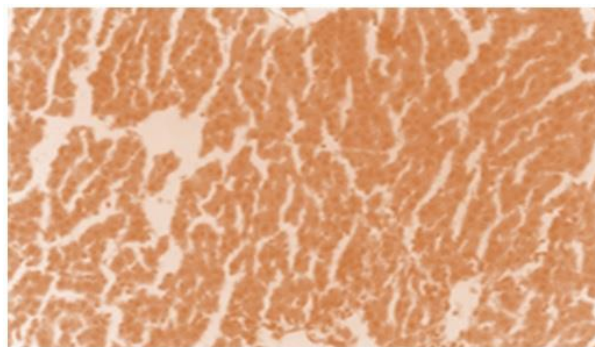
**Figure 8:** Photomicrograph of liver tissue of control (normal) rats showing portal triad with normal hepatocytes.



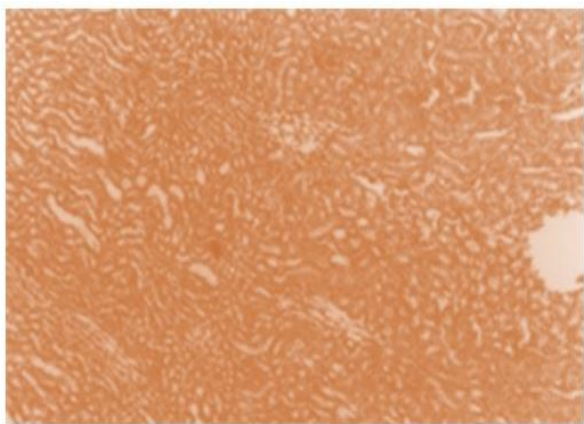
**Figure 9:** Photomicrograph of rat liver tissue of rifampicin treated groups showing necrotic cells around the central vein, fatty changes and inflammatory cells.



**Figure 10:** Photomicrograph of rat liver tissue of rifampicin and Standard treated rats showing Cords of hepatocytes with central vein and portal triads -Mild lymphocytic infiltrate in portal triad vein.



**Figure 11:** Photomicrograph of rat liver tissue of rifampicin and T1 treated rats showing macrophage infiltration and improvement of histological



**Figure 12:** Photomicrograph of rat liver tissue of rifampicin and T2 treated rats showing regenerated tubular epithelium and healing by fibrosis of the necrotic.

### **Histopathology of the liver in rifampicin induced hepatotoxicity studies.**

#### **Discussion**

#### **Estimation of Serum Marker Enzymes**

During hepatic damage, cellular enzymes like AST, ALT and ALP present in the liver cells leak into the serum, resulting in increased concentration.

Rifampicin administration for 9 days significantly increased all these serum enzymes.

Serum levels of SGPT can increase due to damage of the tissues producing acute hepatic necrosis, such as viral hepatitis and acute cholestasis. Rifampicin induced liver damage and alcoholic cirrhosis also can associate with mild to moderate elevation of transaminases.

In the current study treatment of rats with ethanolic extract of whole plant of *Hibiscus platanifolius* significantly ( $p < 0.01$  in 200 mg/kg b.w. and  $p < 0.01$  in 400 mg/kg b.w) decreased the levels of SGPT in serum which is an indication of hepatoprotective activity.

SGOT is a mitochondrial enzyme released from heart, liver, skeletal muscle and kidney. Liver toxicity elevated the

SGOT levels in serum due to the damage to the tissues producing acute necrosis, such as severe viral hepatitis & acute cholestasis.

In the current study treatment of animals with ethanolic extract of *Hibiscus platanifolius* significantly ( $p < 0.01$ ) decreased the levels of SGOT in serum which is an indicative of hepatoprotective activity.

In case of toxic liver, alkaline phosphatase levels are very high, which may be due to defective hepatic excretion or by increased production of ALP by hepatic parenchymal or duct cell. In the current study treatment of animals with ethanolic extract of *Hibiscus platanifolius* significantly ( $p < 0.01$  in 200 mg/kg b.w. and  $p < 0.01$  in 400 mg/kg b.w) decreased the levels of ALP in serum as an indication of hepatoprotective activity.

#### **Direct and Total Serum bilirubin**

In case of toxic liver, bilirubin levels are elevated. Hyperbilirubinemia can result from impaired hepatic uptake of unconjugated bilirubin. Such a situation can occur in generalized liver cell injury. Certain drugs (e.g., rifampin and probenecid) interfere with the net uptake of bilirubin by the liver cell and may produce a mild unconjugated hyperbilirubinemia. Bilirubin level rises in diseases of hepatocytes, obstruction to biliary excretion into duodenum, in haemolysis and defects of hepatic uptake and conjugation of bilirubin pigment such as in Gilbert's disease. In the current study treatment of animals with ethanolic extract whole plant of *Hibiscus platanifolius* significantly ( $p < 0.01$  in 200 mg/kg b.w. and  $p < 0.01$  in 400 mg/kg b.w) decrease the levels of bilirubin (direct and total) in serum which is an indication of hepatoprotective activity.

#### **Cholesterol and Total protein**

A direct relationship exists between your liver function and cholesterol levels. In fact, liver problems can lead to elevated cholesterol levels in blood and vice versa. One of the major

functions of liver is to produce bile, a fluid that helps to digest fats and process cholesterol, If liver damage or inadequate liver function, this function could become impaired, increasing your cholesterol levels.

This can lead to a buildup of fat and cholesterol in liver and blood. Conversely, excessively high cholesterol levels in blood can contribute to liver damage as well. High cholesterol levels can lead to a buildup of fat in liver, potentially causing nonalcoholic steatohepatitis, or NASH, also called "fatty liver disease," Although high cholesterol can contribute to NASH, other liver conditions can cause elevated cholesterol levels.

For example, liver diseases such as alcoholic hepatitis and cirrhosis can lead to high cholesterol.

In the current study treatment of animals with ethanolic extract of *Hibiscus platanifolius* significantly ( $p < 0.01$ ) decreased the levels of Cholesterol in serum which is an indicative of hepatoprotective activity.

Total protein and albumin levels are low; this can be an indication of certain underlying health conditions.

Although the two main proteins are albumin and globulin, albumin is the major protein found in blood plasma. Produced in the liver, albumin has many functions in the body, including the transportation of substances such as hormones and medications.

Total protein test and an albumin in serum test can measure the amounts of blood proteins. A blood test that shows low levels of albumin can be an indication of liver damage or disease. Liver dysfunction associated with decreased albumin levels includes diseases such as hepatitis. Ascites or swelling of abdomen may develop if you have low albumin levels are associated with liver disease.

Decreased albumin levels may also suggest kidney diseases or disorders, including glomerulonephritis. With a kidney

disorder such as glomerulonephritis, albumin is lost from body through urine, which can lead to decreased protein levels.

In the current study treatment of animals with ethanolic extract of *Hibiscus platanifolius* significantly ( $p < 0.01$ ) increased the levels of proteins in serum which is an indicative of hepatoprotective activity.

## Conclusion

The hepatoprotective effect of ethanolic extract of whole plant of *Hibiscus platanifolius* was confirmed by the following measures:

Serum marker enzymes such as SGPT, SGOT, SALP, direct and total bilirubin, showed marked increase. The same is observed in liver diseases in clinical practice and hence are having diagnostic importance in the assessment of liver function.

In the present study, the ethanolic extract of whole plant of *Hibiscus platanifolius* significantly reduced the elevated levels of above mentioned serum marker enzymes and increase in the levels of protein. Hence, at this point it may be concluded that the ethanolic extract of whole plant of *Hibiscus platanifolius* possess hepatoprotective activity.

## References

1. Saleem Mohamed TS, Chetty Madhusudhana C, Ramkanth S, Rajan V.S.T, Kumar Mahesh K, Gauthaman K, Hepatoprotective Herbs (2010). A Review, International. Journal of research of pharmacy and science. 1-5.
2. Kurian JC (2007). Plants that Heals, Oriental Watchman Publishing House, Pune. 1-53.
3. Noorani Arsadali (2010). Journal of scientific speculation and research. 1: 25-29.
4. Momin (2002). A, Role of Indigenous Medicine in Primary Health Care, International seminar on unani medicine, New Delhi, India.54.

5. Eileen Kaner, Newbury Dorothy Birch, Leah Avery, Katherine Jackson, Nicola Brown, Helen Mason (2007). A Rapid Review of Liver Disease Epidemiology, Treatment and Service Provision in England, Institute of Health and Society, Newcastle University.
6. Saleem Mohamed TS, Chetty Madhusudhana C, Ramkanth S, Rajan VST, Kumar Mahesh K, Gauthaman K, Hepatoprotective Herbs – A Review. 1: 1-5.
7. Bhardwaj Akhil, Khatri Pankaj, Soni ML, Ali DJ (2011). Potent Herbal Hepatoprotective Drugs - A Review, Journal of Advanced Scientific Research. 2: 15-20.
8. Jmelnitzky AC, Guidi M, Bologna A, Viola M, Soccini C, Barbero R, Belloni P, Apraiz M (2000). Clinic-epidemiological significance of drug hepatotoxicity in liver disease consultation. 30: 77-84.
9. Arago George, Zobair M, Younossi (2010). Clevel and Clinical Journal of Medicine. 77: 195-204.
10. Fauci Kasper Braunwald, Jameson Hauser Longo (1808-1869). Harrison's Principles of Internal Medicine. 16.
11. Dwivedi Shakti, Khatri Pankaj, Rajwar Sonam, Dwivedi Anup (2011). Pharmacognostic and Pharmacological Aspects of Potent Herbal Hepatoprotective Drugs-A Review, International Journal of Research in Pharmaceutical and Biomedical Sciences. 2
12. Walker Roger, Whittlesea Cate Clinical Pharmacy and Therapeutics. 4: 222-224.
13. Srivastav Saurabh, Singh Pradeep, Mishra Garima, Jha K.K, Khosa RL, Achyranthes aspera (2011). An important medicinal plant, A review Journal Natural Production Plant Resources. 1: 1-14.